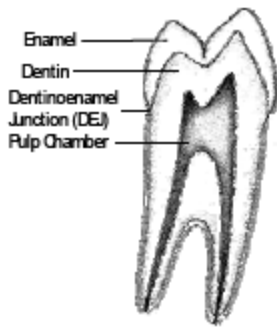


Dental Care for People with Osteogenesis Imperfecta

Introduction

Osteogenesis imperfecta (OI) is always associated with bone fragility. In addition, OI may affect the growth of the jaws and may or may not affect the teeth. About half of the people who have OI have teeth that appear normal, and their major concerns are routine care. However, the other half has a defect in the teeth called dentinogenesis imperfecta (DI), sometimes referred to as opalescent teeth or brittle teeth. These teeth may be misshapen, may chip or break easily, and will require special care. Oral cavity problems related to osteogenesis imperfecta may include the following:

- **A skeletal Class III malocclusion.** The teeth do not correctly match up making biting difficult. This is caused by the size and/or position of the upper jaw or the lower jaw.
- **An open bite.** There is a vertical gap between some of the upper and lower teeth.
- **Impacted teeth.** The first or second permanent molars do not erupt, or they erupt out of the usual location (ectopic).
- **Dental development.** Tooth development may be delayed or advanced in some individuals affected by OI. OI does not affect the presence or absence of gum disease (periodontitis).



Major Parts of the Teeth

The teeth are made up of four distinct parts.

- **Enamel** is the outside part of the crown. It is the hardest substance in the body and the point of contact for chewing.
- **Dentin** is the substance under the enamel that forms the rest of the crown and surrounding the pulp chamber and almost all of the root structure. It is similar to bone.
- The **Pulp Chamber** is the inner hollow part of the tooth containing blood vessels and nerves.
- The **Dentinoenamel Junction (DEJ)** is the term for where the enamel and dentin are attached to each other.

Dentinogenesis Imperfecta (DI)

Dentinogenesis imperfecta can be part of osteogenesis imperfecta (DI type I) or it can be a separate inherited dominant trait without OI (DI type II). DI occurring with OI seems to run in families but can vary in severity from one member to another. DI has a variable affect on the color, shape, and wear of both primary and permanent teeth. If someone has OI and DI, all of their teeth may not be affected to the same degree.

Teeth affected by DI have essentially normal enamel, but the DEJ and the dentin are not normal. The enamel tends to crack away from the dentin, which will wear away more quickly than enamel. The dentin makes the teeth look darker or opalescent. The dentin also grows to fill in the pulp chamber, causing a loss of feeling in the tooth. Affected teeth will have an increased incidence of fracture, wear and decay.

Dentinogenesis imperfecta may be diagnosed with the first baby tooth. If the tooth looks gray, bluish, or brown, DI should be suspected. Children should be taken to a dentist (if possible a specialist in pediatric dentistry) when the first teeth are erupting. This may happen as early as 6 months to 1 year of age. Radiographs, or X-rays, can be useful but may be difficult to obtain until the child is older. Sometimes there are changes visible on the X-rays that are not obvious just by looking at the teeth. Crowns appear bulbous and roots may be shorter and more slender than standard. Primary teeth are usually more affected than the permanent teeth.

When, for any reason, crowns are not feasible, a “tooth color” dental material may be used, such as composites or glass ionomers in conjunction with composites. The sand abrasion method may also be useful because it removes carious dentine only and thus spares dental tissue. In any case, amalgam restorations should not be used because they impose an additional stress on the teeth.

General Care for People With OI and Without DI

A dentist should see a child with OI by **6 months after the eruption of the first baby tooth** at the latest. Baby teeth require care. They are important for chewing, speaking, holding space for the permanent teeth to grow in, and growth of the jaws. There appears to be minimal risk of jaw fracture from routine dental care and dental extractions. No particular precautions are needed other than those that would be taken anyway, such as support of a very thin lower jaw when an extraction procedure is being done.

Good care involves brushing and flossing the teeth of young children, then teaching them how to do it themselves and checking them as they grow older. Soft toothbrushes are good for everybody and easier on gums, since gums also need brushing. Mechanical toothbrushes tend to be more effective than brushing by hand. Use of fluoride toothpaste is recommended. Children should use a small dab of toothpaste, or a children's toothpaste, and be taught to spit it out well after brushing so they do not swallow excessive amounts. Before going to bed, children should spit out the toothpaste after brushing, but not rinse their mouths. This will leave more fluoride in the mouth to work overnight. Parents should talk to their child's dentist about the fluoride content of their drinking water and ask if supplemental fluoride is needed from a pill, a non-alcohol fluoride rinse, or a fluoride gel. Sealants placed on the biting surface of the permanent molars in children may reduce the chance of developing cavities in the grooves of the teeth.

Starting when the child is 7 years old, an orthodontist should check the child's bite for evidence of an open bite or Class III malocclusion.

General Care for People with OI Plus DI

Children with OI and dentinogenesis imperfecta need the same basic care as discussed above, but they also need to be monitored for cracking, chipping and abrasion of the teeth. Special care will be needed even with the baby teeth. All of the teeth may not be affected by DI, and primary teeth usually are affected to a greater extent than the permanent teeth. Restorative treatment may be needed at some point.

Regular care is needed so the teeth will last as long as possible and to prevent abscesses and pain. Brushing and cleaning has not been shown to cause damage, but will not make teeth affected by DI white. Sealants should be effective on teeth affected with DI as long as the enamel is intact.

Older children and especially adolescents with DI are often embarrassed by their discolored teeth. Different types of veneers can sometimes hide the problem. Bleaching is not recommended because the discoloration is not in the enamel. If the teeth are wearing excessively, caps (also called crowns), will probably need to be placed on at least some of the teeth. Caps serve to keep the teeth in place and encourage proper development of the jaw. More specialized treatment may be more appropriate for permanent teeth.

Treating Malocclusions with Orthodontia or Orthognathic Surgery

A malocclusion is an abnormal relationship between the upper and lower teeth, which creates problems with how the teeth come together. This may be due to the relationship of the upper and lower jaws to each other, the alignment of the teeth, or both. This type of problem includes crooked teeth, "under bite," "overbite" and "open bite." Treatment is usually provided by an orthodontist. The particular treatment plan depends on the specific problem(s) with the bite and the teeth. If the malocclusion is caused by skeletal discrepancies, then orthognathic (jaw) surgery may be required along with orthodontia.

An orthodontist should examine each child with OI around the age of 7 years. At that time early orthodontic interventions in children who are developing a relatively small upper jaw compared to the lower jaw may help decrease the need for later orthognathic surgery.

Although there are only a few case reports and no published studies regarding orthodontia for people with OI, it seems to be safe to treat them if DI is not present. If DI is present, the orthodontist will have to decide if the enamel is strong enough for braces. Unfortunately, it is difficult to determine how strong the enamel is until it is tried.

Conventional practice involves gluing brackets to the teeth for the braces and removing the brackets later. Plastic brackets can be used instead of metal brackets because they can be removed with a hand piece without disturbing the fragile enamel. If there is concern about the enamel cracking off and treatment is still desired, placing bands on all the teeth to hold the brackets may work. Although bands are considered an “old fashioned” method, the technique still works. It may be necessary to seek out an older orthodontist who learned to install braces before the current practice of gluing bands directly to teeth was discovered. The orthodontist will need to minimize forces on the teeth as well as movement of teeth over long distances. The wires which are attached to the bands should initiate slow and light movements. Whenever possible, removable orthodontic appliances are preferred. Caps, or crowns, may also be effective in correcting rotations or mildly malpositioned teeth.

In some children with OI the upper jaw, or maxilla, does not grow as much as the lower jaw, or mandible. Sometimes the way that both jaws grow makes it difficult, if not impossible, to bring the teeth together properly, even after orthodontic braces. If the malocclusion is due to a problem with the growth of one or both jaws, then a combination of orthodontic braces and orthognathic surgery may be used to align the teeth. Some period of orthodontic braces is also usually needed after the jaw surgery. There are a few published reports about these surgeries indicating good post-operative healing of the jaws. The same concerns that one would have with any surgery in people with OI, such as potential bleeding problems and reaction to general anesthesia, still apply. Furthermore, the recent use of bisphosphonates to treat different bone disorders triggers many additional questions regarding maxillo facial surgeries.

Treating Impacted Teeth

The dentist needs to consider if the impacted teeth should be left alone or extracted, or if an attempt should be made to move them into a functional position in the mouth. To move a tooth, a coordinated effort is needed between the oral surgeon and the orthodontist to surgically uncover the impacted tooth and glue an attachment onto the tooth so that light force from the braces can be used to bring the tooth into the proper position. The orthodontist may also use braces prior to surgery to be sure there is space to bring the impacted tooth into the proper position.

Other Treatments

Dental Implants are used to replace missing teeth. Theoretically it is possible to do this successfully for a person with OI and there is anecdotal evidence that this has been accomplished. However, there are no controlled studies on the use of dental implants in people with OI and only a few case reports in the literature. The high failure, reported to be 50 per cent within 3 years of surgery is a concern.

Dental implants are somewhat like screws. In order to function, there must be enough bone in the jaw for the implant to be securely placed. After healing, a “post” is placed in the implant and an artificial tooth is attached. Good, strong healing around the implant is critical.

Veneers are cosmetic coverings typically placed on the outer surface of the upper anterior teeth. Anterior teeth are seen when a person smiles. Sometimes adults, often older children and especially adolescents with DI resent the color of their teeth. Adults can have veneers or crowns placed to change the appearance of the anterior “smiling teeth.” but older children and adolescents are too young to receive permanent restorations. They can be good candidates for composite veneers. Veneers can last for years and have the merit of being relatively inexpensive, versatile and are effective for hiding unsightly tooth color. However, veneers are not typically made to withstand biting forces. Recommendations for this type of treatment are made on a case by case basis.

Caps and Bridges have a variety of uses. Caps, also called crowns, are made of metal or ceramic and cover the entire tooth after the enamel is removed. If teeth are wearing excessively, crowns usually provide the best treatment. Preformed stainless steel crowns are typically used for baby teeth, while cast metal or ceramic crowns are used for adult teeth. If there is not enough tooth left above the gum to place a crown, the individual may need gum surgery to make the part of the tooth showing above the gum larger. The surgeon may place a post down into the root of the tooth to act as a reinforcing rod, and then rebuild part of the tooth above the gum for the crown to sit on. In teeth not affected with DI, root canal treatment may be needed if the nerves and blood vessels inside the tooth are infected from a cavity or if the post needs to go down the center of the root(s).

In teeth with DI, the inside where the nerves and blood vessels are normally located may already be filled with dentine. This makes placing a post in the center of the root and/or root canal treatment difficult, if not impossible. Small reinforcing pins may be placed in the dentine away from the center of the root to help make the new crown of the tooth stronger.

A bridge is at least one artificial tooth attached to one or more crowns. A bridge is sometimes called a fixed partial denture.

Complete Dentures are used when there are no teeth remaining in one or both jaws. How well the denture fits depends on how much bone remains after the teeth are lost. There are no studies that compare bone loss under dentures in people with OI to people without OI. The bone loss that occurs when teeth are lost is a resorption of the bone, not a fracture process, so it is not known if bone loss would be more rapid in people with OI. Complete dentures in children and adolescents who are still growing will need to be adjusted and or remade on a routine basis to compensate for growth in the jaw.

Removable Partial Dentures are used when some teeth remain in one or both jaws. A denture, typically made with a metal framework for strength and retention, is constructed to replace missing teeth.

Bisphosphonates

A group of drugs known as bisphosphonates are a common treatment for many bone disorders including OI. People with OI may receive pamidronate (Aredia®) and zoledronic acid (Zometa®) given by intravenous infusion, and alendronate (Fosamax®), risedronate (Actonel®), and ibandronate sodium (Boniva®) given in tablet (oral) form. Reports in medical journals suggest the possibility of a link between bisphosphonates and areas of dead bone (osteonecrosis) in the jaw in people in the general population. Information to date indicates that children who have been treated with bisphosphonates at doses appropriate for OI have not developed this problem. This has not been studied in adults who have OI. People with OI taking a bisphosphonate should be closely monitored by a doctor and a dentist. Good oral hygiene along with regular dental care to prevent infections or periodontal (gum) disease lowers risk. When possible, required dental surgery should be scheduled prior to starting bisphosphonate treatment or after treatment is finished. Bisphosphonate treatment should not be resumed until after the surgical area is healed. Elective jaw surgery, including dental implants, should be avoided during intravenous bisphosphonate therapy.

Locating a Dentist

There is no national list of dentists who treat people with OI. Schools of dentistry or the dental department at major medical centers may be helpful in locating dentists who are familiar with OI and DI. The American Academy of Pediatric Dentistry is a good source of pediatric dentists, although any particular member of this group may or may not see OI patients. Contact the Academy at:

American Academy of Pediatric Dentistry
211 East Chicago Avenue, #700
Chicago, IL 60611-2663
Telephone: (312) 337-2169
Fax: (312) 337-6329

This fact sheet was prepared with assistance from James K. Hartsfield, Jr., D.M.D., Ph.D., FACMG from the University of Kentucky College of Dentistry, and Stephane Schwartz, DDS, MSD, FRCD(c) Montreal Children's Hospital, McGill University. Revised April 2007, December 2016.

Dental/orthodontic insurance, or medical insurance that covers dental diagnosis and treatment as a part of having OI, may cover some of the costs of dental care for people with OI. Some states also have financial assistance programs that may provide assistance.

This fact sheet was prepared with assistance from James K. Hartsfield, Jr., D.M.D., Ph.D., FACMG from the University of Kentucky College of Dentistry, and Stephane Schwartz, DDS, MSD, FRCD(c) Montreal Children's Hospital, McGill University. Revised April 2007, December 2016.